

Fratura bilateral do osso temporal: reabilitação auditiva de um caso raro

Caso Clínico

Autores

Sara Raquel Azevedo

Unidade Local de Saúde de Santo António, Porto, Portugal

João Vale Lino

Unidade Local de Saúde de Santo António, Porto, Portugal

Miguel Bebiano Coutinho

Unidade Local de Saúde de Santo António, Porto, Portugal

Luís Meireles

Unidade Local de Saúde de Santo António, Porto, Portugal

Resumo

As fraturas do osso temporal e as sequelas associadas devem ser avaliadas e tratadas precocemente por um otorrinolaringologista, de forma a melhorar o resultado funcional a longo prazo.

O nosso objetivo com a apresentação deste caso foi descrever o caso raro de um paciente com uma hipoacusia incapacitante e arreflexia vestibular causadas após uma fratura bilateral do osso temporal. Foi possível a reabilitação auditiva com implante coclear num ouvido e prótese auditiva no outro ouvido.

O paciente deu consentimento para publicar o caso. Palavras-chave: osso temporal; fratura; implante coclear; prótese auditiva

Introduction

Temporal bone trauma accounts to approximately 20% of skull base fractures¹. Temporal bone fractures are associated with damage to multiple structures like facial nerve, vestibule-cochlear nerve, cochlea, labyrinth, middle ear, external auditory canal, temporomandibular joint, jugular vein, carotid artery and others². Usually, road traffic accidents, assaults and falls are the main cause of temporal bone fractures³. Every patient with a temporal bone fracture must be assisted by an otolaryngologist⁴. A new classification divides temporal bone fractures in “optic capsule sparing” versus “optic capsule disrupting”. This classification gives more prognostic information than the classic one³. “Optic capsule disrupting” fractures are associated with a higher incidence of audiovestibular function loss⁵. Mechanisms behind hearing loss are associated with disruption of the membranous labyrinth, damage to the cochlear nerve, cochlear blood supply interruption, perilymph fistula, and endolymphatic hydrops^{6,7}. When there

Correspondência:

Sara Raquel Azevedo
saraquelaazevedo@gmail.com

Artigo recebido a 20 de Maio de 2024.
Aceite para publicação a 25 de Setembro de 2024.

is an involvement of the optic capsule with a cochlear nerve intact causing an acute severe-to-profound hearing loss, patients become candidates to cochlear implantation¹. It is important to always try a binaural hearing rehabilitation in acutely deaf patients.

We present a case of a 31-year-old man who deafened by bilateral temporal bone fracture and achieved satisfactory aural rehabilitation with cochlear implantation and hearing aid.

Case report

A 31-year-old construction worker man was seen in the emergency department after a fall of 1,5 meters high, approximately. He reported sudden onset of bilateral hearing loss, worse in the left ear and imbalance, with inability to walk. Examination was carried out in the emergency room on a hard plane and, therefore, limited to what is possible to evaluate: patient was conscious, collaborative and with a fluid speech; normal oculomotricity, without spontaneous or gaze-evoked nystagmus; skew deviation absent; facial expression preserved; otoscopy showed a normal external auditory canal and tympanic membrane, without evidence of hemotympanum or cerebrospinal fluid leakage; acumetry: did not discriminate any sound, bilaterally; battle sign and raccoon eyes

absent; anterior rhinoscopy without evidence of rhinorrhachia. A high-resolution temporal bone computed tomography (CT) taken after the trauma revealed bilateral temporal bone fractures: in the right ear, an “Optic capsule disrupting” fracture that intercepts the vestibule and the anterior aspect of the lateral canal semicircular, inferiorly was seen; in the left ear, an “Optic capsule disrupting” fracture that intercepts superior and posterior canal semicircular, vestibule and basal turn of the cochlea (figure 1). Middle ear structures and facial nerve were intact on both sides. Magnetic Resonance Imaging was not performed.

The patient started antibiotic therapy with ceftriaxone 2g every 12 hours and corticosteroid therapy with dexamethasone 4mg every 12 hours. Forty-eight hours after the fall, an audiometry was performed and showed a third degree profound hearing loss (pure tone average (PTA) approximately 116 dB) in the right ear and a total hearing loss in left ear (PTA 120 dB), according to *International Bureau for Audiophonology*⁸ (figure 2). To evaluate the vestibular function, a video head impulse test was performed and showed a bilateral hyporeflexia/areflexia (bilaterally pathological horizontal angular VOR gain <0.6)⁹ (figure 3). While still hospitalized, he began vestibular rehabilitation with gait training. Reassessment

Figure 1
CT scan showing the findings in the right and left ear

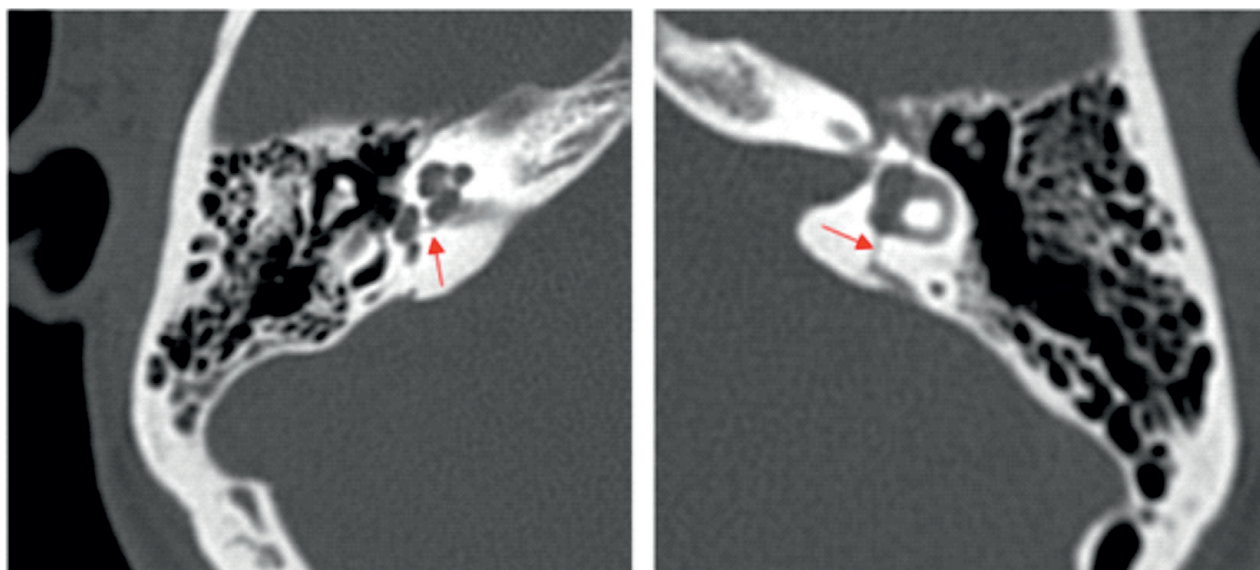


Figure 2
Tonal audiometry three days after the fall

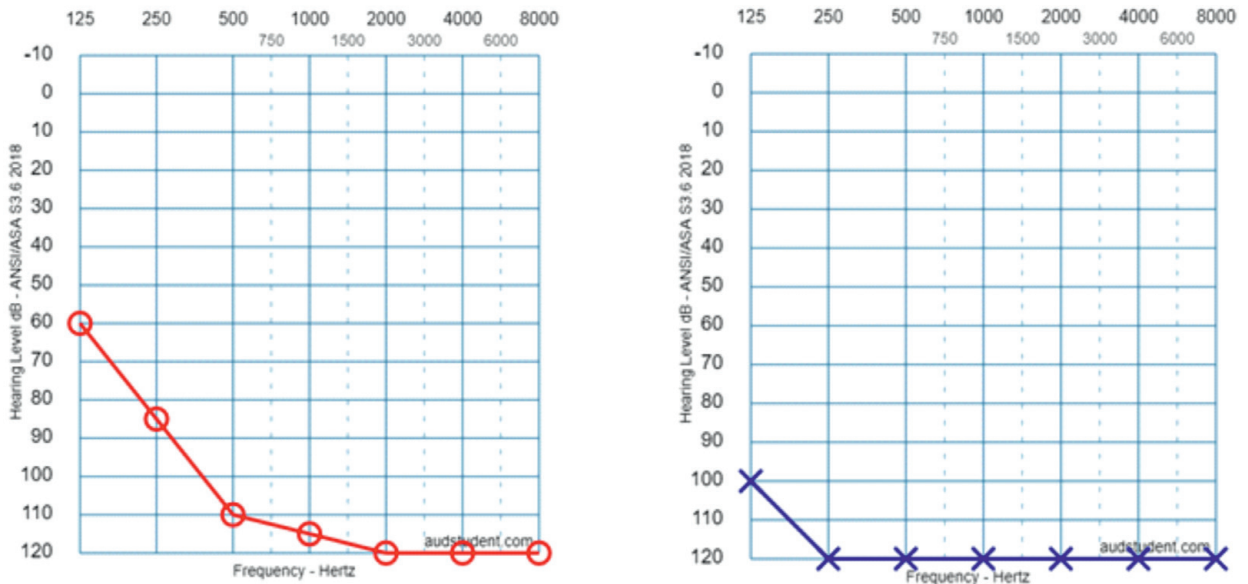


Figure 3
Video head impulse test showing a bilateral vestibular areflexia

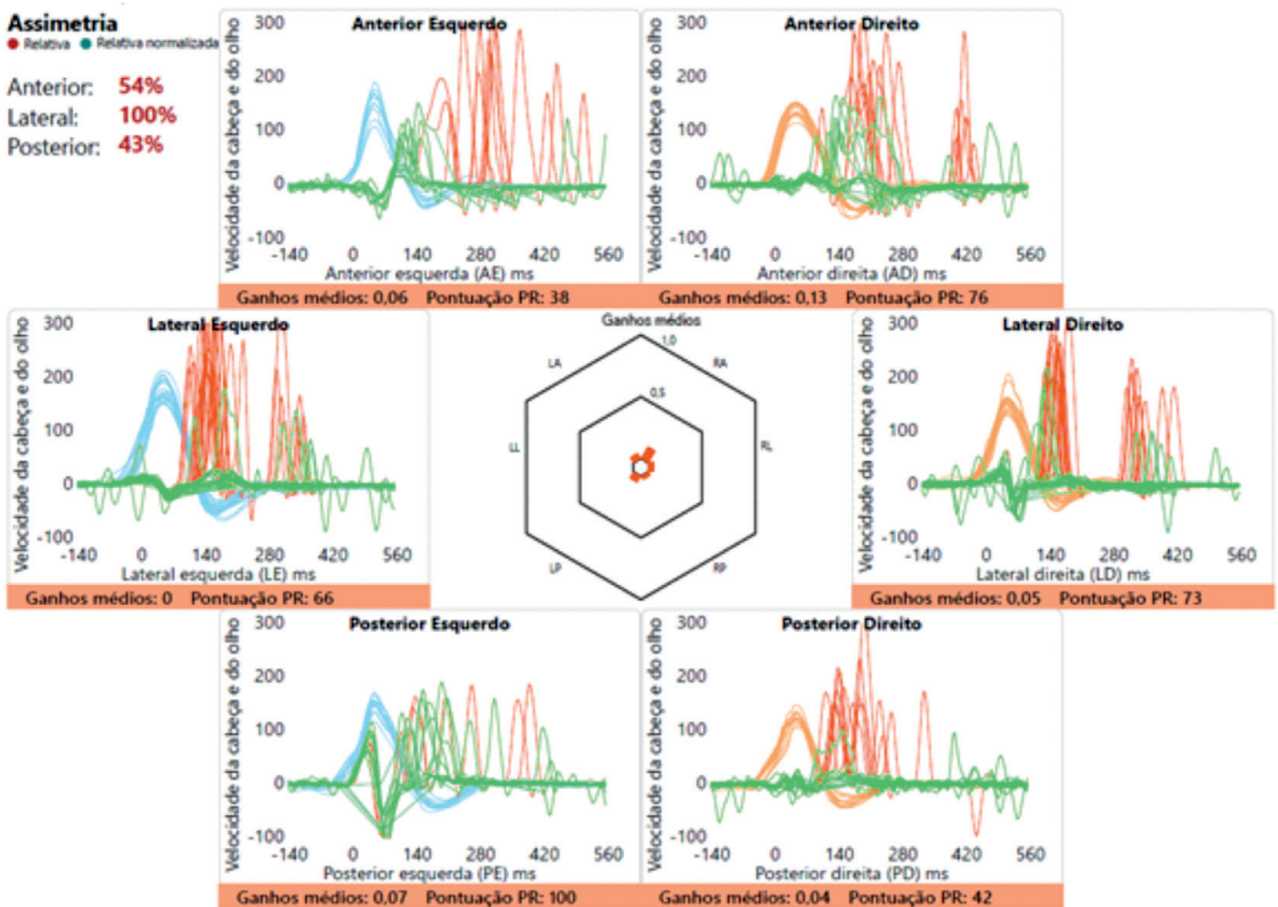


Figure 4
Tonal audiometry ten days after the fall

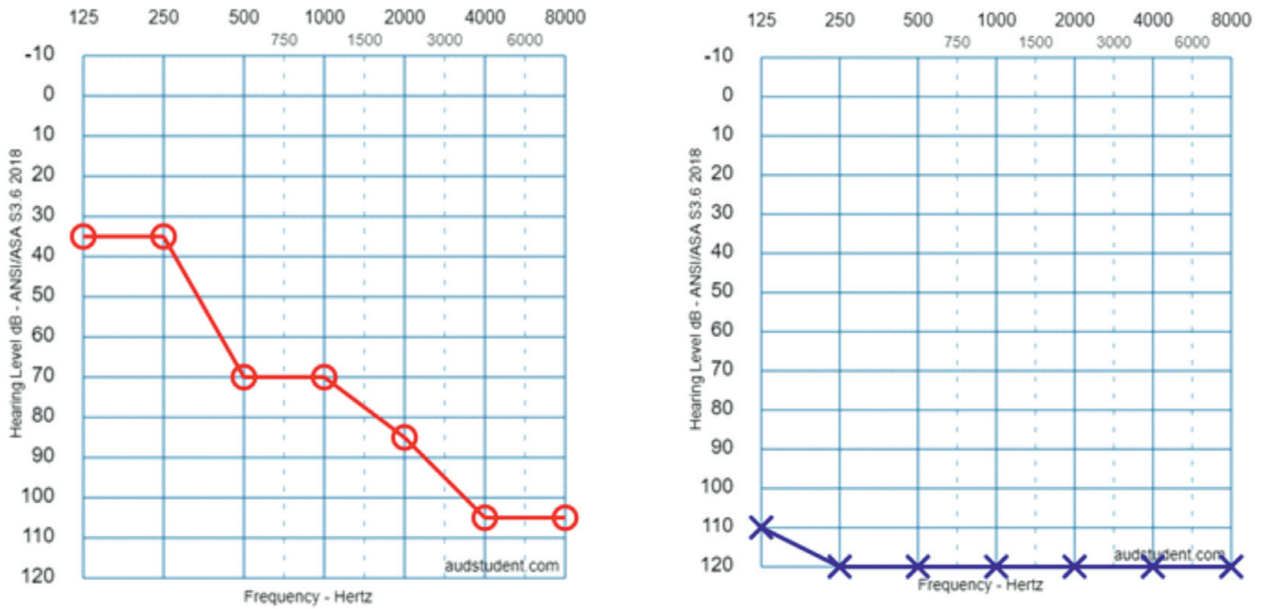
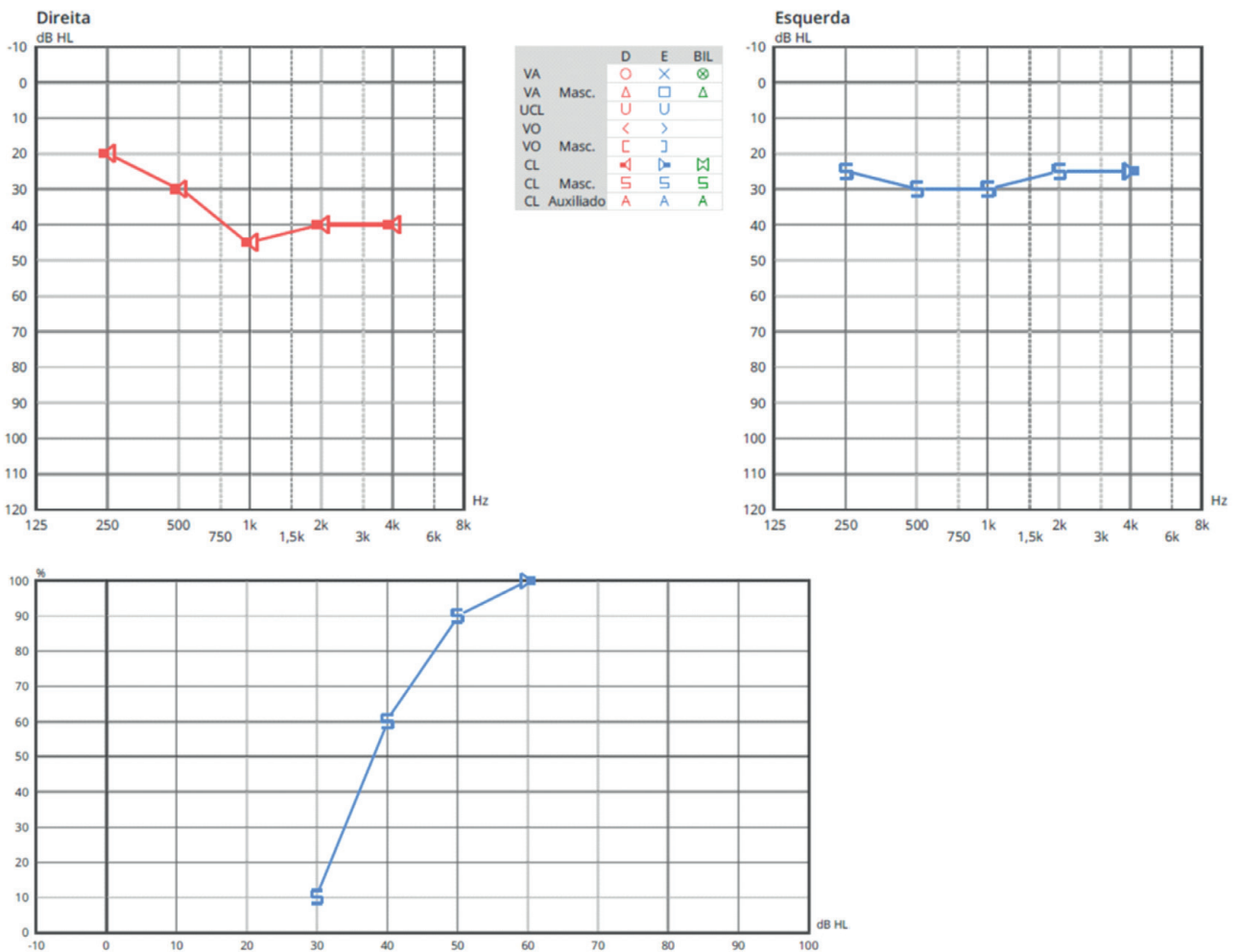


Figure 5
Tonal audiometry showing the results of aural bilateral rehabilitation with hearing aid in the right ear and CI in the left ear, one year after the fall. Vocal audiometry with CI



with the video head impulse test after starting vestibular rehabilitation was not performed. Ten days after, the patient repeated the audiometry and there was an improvement in the right ear pure tone average (116dB to 83dB) and a discrimination of 70%. On the left ear, there was not an improvement in thresholds (figure 4). It was decided to try rehabilitation with a hearing aid on the right ear, with good functional gain (PTA 39 dB). One month after fall, the patient underwent cochlear implantation on the left ear, without complications. Figure 5 shows tonal audiometry with the results of aural bilateral rehabilitation with hearing aid in the right ear and CI in the left ear and vocal audiometry with CI. Vocal audiometry with hearing aid in the right ear wasn't performed.

Discussion

Patients suffering from bilateral temporal bone trauma associated with hearing loss may benefit from cochlear implantation if the functions of the auditory nerves and brain are intact⁵. The ideal time for cochlear implantation in these cases is debatable, and there is no defined consensus in the literature, for now. On one hand, if an early implantation is the decision, may not be giving the necessary time for a spontaneous recovery without any type of intervention; on other hand, it is known that temporal bone fractures can result in hair cells loss, supporting cells and ganglion cells destruction. Therefore, it is expected that the less time passes since the trauma and the surgery, the fewer cells will be damaged, which leads to a higher probability of effective rehabilitation⁴. If proceeding with the implantation is too late, can lead to cochlear ossification and total insertion of the electrode array is not possible¹⁰.

Therefore, many factors have to be considered for cochlear implantation in patients with temporal bone fractures. Preoperative imaging, with high-resolution computed tomography and magnetic resonance imaging is recommended to assess the extent of the fracture and continuity of

the vestibulocochlear nerve, supported by audiological assessment⁷. In fractures with "optic capsule disrupting" not only cochlear function is abnormal, vestibular function can also be missing¹¹. It is mandatory to initiate vestibular rehabilitation in order to promote central compensation through neuroplasticity mechanisms of the central nervous system¹². In the case above described, it is possible to see the evolution of a fracture in which there was partial recovery of hearing and the other without recovery³. Different approaches were used for auditory rehabilitation in this patient, successfully. Hearing difficulty is a well-documented complication of head trauma. When hearing loss is bilateral and sudden, it has a major impact on patients' quality of life. Thus, the goal is to improve their hearing function with aural rehabilitation.

Disclosure Statement

The authors report there are no competing interests to declare.

Data Confidentiality

The authors declare that they followed the protocols of their work in publishing patient data.

Human and animal protection

The authors declare that the procedures followed are in accordance with the regulations established by the directors of the Commission for Clinical Research and Ethics and in accordance with the Declaration of Helsinki of the World Medical Association.

Privacy policy, informed consent and Ethics Committee Authorization

The authors declare that they have written consent for the use of patient photographs in this article.

Financial support

This work did not receive any grant contribution, funding or scholarship.

Scientific data availability

There are no publicly available datasets related to this work.

References

1. Vermeire K, Brokx JP, Dhooge I, Van de Heyning PH. Cochlear implantation in posttraumatic bilateral temporal bone fracture. *ORL J Otorhinolaryngol Relat Spec.* 2012;74(1):52-6. doi: 10.1159/000335931.
2. Suligavi SS, Saiyad SN, Doddamani SS, Mathri A. Early diagnosis of hidden hearing loss following temporal bone fractures. *Indian J Otolaryngol Head Neck Surg.* 2022 Dec;74(Suppl 3):4336-4340. doi: 10.1007/s12070-021-02933-x.
3. Diaz RC, Cervenka B, Brodie HA. Treatment of temporal bone fractures. *J Neurol Surg B Skull Base.* 2016 Oct;77(5):419-29. doi: 10.1055/s-0036-1584197.
4. Prasad BK, Basu A, Sahu PK, Rai AK. A study of otological manifestations of temporal bone fractures. *Indian J Otolaryngol Head Neck Surg.* 2022 Aug;74(Suppl 1):351-359. doi: 10.1007/s12070-020-02111-5.
5. Chung JH, Shin MC, Min HJ, Park CW, Lee SH. Bilateral cochlear implantation in a patient with bilateral temporal bone fractures. *Am J Otolaryngol.* 2011 May-Jun;32(3):256-8. doi: 10.1016/j.amjoto.2010.03.002.
6. Poupore NS, Britt AF, Nguyen SA, White DR. Complications after pediatric temporal bone fractures by classification system: a systematic review and meta-analysis. *Otolaryngol Head Neck Surg.* 2024 Apr;170(4):1009-1019. doi: 10.1002/ohn.638.
7. Eastwood M, Biggs K, Metcalfe C, Muzaffar J, Monksfield P, Bance M. Outcomes of cochlear implantation in patients with temporal bone trauma: a systematic review and narrative synthesis. *J Int Adv Otol.* 2021 Mar;17(2):162-174. doi: 10.5152/JIAO.2021.9228.
8. International Bureau for Audiophonology BIAP Recommendation 02/1: Audiometric Classification of Hearing Impairments. [Internet] Available from: <https://www.biap.org/fr/recommandations/recommandations/tc-02-classification/213-rec-02-1-en-audiometric-classification-of-hearing-impairments/file>
9. Strupp M, Kim JS, Murofushi T, Straumann D, Jen JC, Rosengren SM. et al. Bilateral vestibulopathy: diagnostic criteria consensus document of the classification committee of the barany society. *J Vestib Res.* 2017;27(4):177-189. doi: 10.3233/VES-170619.