

# Transnasal endoscopic orbital decompression in graves' disease: experience of 20 years in a tertiary hospital

## Review Article

### Authors

- Luís André Baptista**  
Centro Hospitalar de Lisboa Ocidental (CHLO), Portugal
- Tiago Colaço**  
Centro Hospitalar de Lisboa Ocidental (CHLO), Portugal
- Margarida Baptista**  
Centro Hospitalar de Lisboa Ocidental (CHLO), Portugal
- Luís Castelhana**  
Centro Hospitalar de Lisboa Ocidental (CHLO), Portugal
- Filipe Correia**  
Centro Hospitalar de Lisboa Ocidental (CHLO), Portugal
- Mariana Donato**  
Centro Hospitalar de Lisboa Ocidental (CHLO), Portugal
- Vítor Oliveira**  
Centro Hospitalar de Lisboa Ocidental (CHLO), Portugal
- Deodato Silva**  
Centro Hospitalar de Lisboa Ocidental (CHLO), Portugal
- Pedro Alberto Escada**  
Centro Hospitalar de Lisboa Ocidental (CHLO), Portugal

**Correspondence:**  
Luís André Baptista  
baptista.la24@gmail.com

Article received on July 14, 2023.  
Accepted for publication on August 5, 2024.

### Abstract

**Introduction and goals:** Graves' orbitopathy is the most common extrathyroidal manifestation of Graves' disease and manifests as proptosis, exposure keratitis and compressive optic neuropathy. Its treatment, particularly when refractory to medical therapies, involves surgical decompression of the orbit. The objective of this work is to evaluate the effectiveness and safety of transnasal endoscopic decompression of the orbit. **Methods:** Retrospective analysis of patients who underwent this procedure between January 2001 and December 2022. Patients were evaluated before and after surgery regarding the presence of ophthalmological symptoms, and changes in the following parameters: visual acuity, intraocular pressure and proptosis. Surgical complications were also recorded. **Results:** The study included 40 orbits from 27 patients. In the ophthalmological evaluation, on average, intraocular pressure reduced by 2.7 mmHg ( $p < 0.001$ ), proptosis reduced by 3.98 mm ( $p < 0.05$ ) and visual acuity improved by 2/10 of vision ( $p < 0.001$ ). No complications were recorded except for new diplopia in 7 patients (25.9%). **Conclusion:** Transnasal endoscopic decompression of the orbit showed good results in terms of safety and efficacy, although the development of postoperative diplopia is not negligible. **Palavras-chave traduzidas:** Graves' disease; thyroid orbitopathy; endoscopic orbital decompression; diplopia

**Introduction**  
Thyroid orbitopathy (TO) results from the stimulation of orbital fibroblasts by autoantibodies against the thyroid-stimulating hormone (TSH) receptor, which induces lymphocytic infiltration and glycosaminoglycan deposition.<sup>1</sup> This results in increased orbital fat and connective tissue, which presents as proptosis, diplopia,

exposure keratitis and, in 5–10% of cases, compressive optic neuropathy (CON).<sup>2</sup> The treatment of TO depends on its severity and may involve immunosuppression, radiotherapy, and orbital decompression surgery (ODS), with the European Group on Graves' Orbitopathy (EUGOGO) providing well-established guidelines for these treatments.<sup>3</sup> The literature includes 18 techniques for ODS, including combined techniques. More aggressive techniques, such as the coronal or transantral approaches, have been gradually replaced by minimally invasive methods, including the endoscopic, transconjunctival, and transcaruncular approaches.<sup>4</sup> The ideal surgical approach remains controversial and is usually influenced by the presence of CON and extent of proptosis. The endoscopic approach enables the decompression of the medial orbital wall up to the orbital apex and demonstrates better outcomes in cases of optic nerve damage.<sup>5</sup> Proptosis reduction is directly proportional to the number of orbital walls targeted for decompression. However, targeting more walls can lead to an increased risk of postoperative complications.<sup>6</sup> The aim of this study was to evaluate the

effectiveness and safety of transnasal endoscopic orbital decompression.

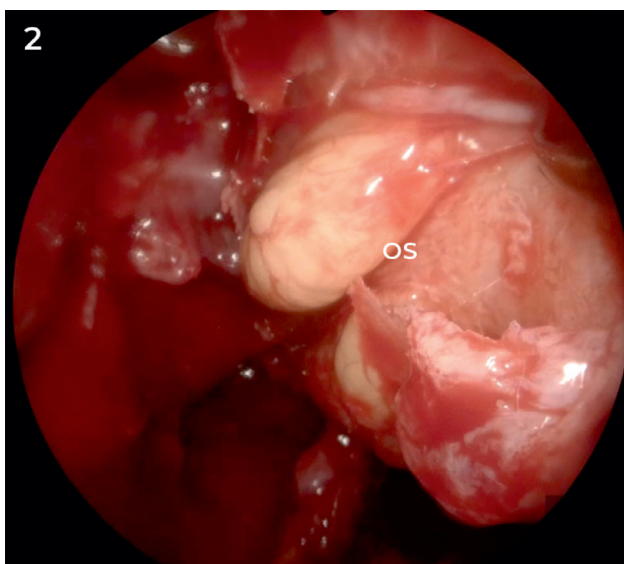
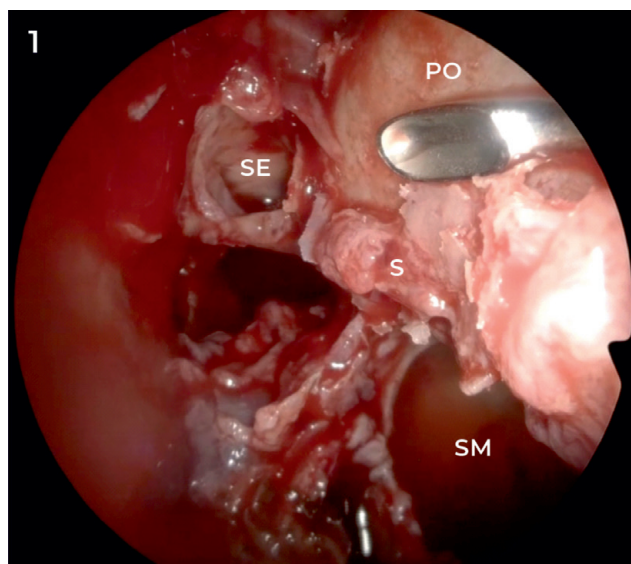
## Materials and methods

This observational, retrospective, and descriptive study was conducted at the Otorhinolaryngology Service of the Egas Moniz Hospital, Unidade Local de Saúde de Lisboa Ocidental (CHLO), between January 2001 and December 2022. We analyzed the clinical records of all patients who underwent transnasal ODS. Patients selected for ODS had TO causing ocular discomfort due to exposure keratopathy, CON, or disfiguring proptosis.

Preoperatively, the patients underwent a comprehensive eye examination that included exophthalmos measurement using a Hertel exophthalmometer, intraocular pressure measurement using a Goldmann applanation tonometer, and visual acuity measurement using the Snellen chart. The values measured in the last preoperative examination and postoperatively approximately four weeks after surgery were recorded. Demographic data, indications for surgery, surgical or postoperative complications, and follow-up information were also analyzed.

**Figure 1**

1: Intraoperative transnasal endoscopic decompression of the left orbit showing the maxillary sinus (MS), sphenoid sinus (SS), and periorbital (PO) area after removal of the lamina papyracea and before removal of the inferomedial orbital strut (IOS). 2: Intraoperative orbital sling (OS) over the medial rectus muscle and modified orbital strut.



All patients underwent maxillary sinusotomy, total ethmoidectomy, and ipsilateral sphenoidotomy, followed by decompression of the medial and inferior orbital walls, with the infraorbital nerve serving as the lateral boundary for dissection. In some cases, the surgeon opted to preserve an inferomedial bony strut or medial periorbital strip (orbital sling) (figure 1).

Statistical analysis was performed using SPSS software version 23.0 (IBM Corp., Armonk, NY, USA). The Wilcoxon test was used to compare the pre- and postoperative values. A p-value < 0.05 was considered statistically significant.

Results

A total of 40 orbits were identified in 27 patients undergoing ODS for TO. The mean age at the time of surgery was 54.1 (31–79) years, and the sample included 10 men (37%) and 17 women (63%). Other demographic results are described on table 1.

Orbital signs at presentation included proptosis in 40 (100%) eyes, keratopathy in 28 (70%) eyes, optic neuropathy in 25 (62.5%) eyes, and diplopia in 13 (48.1%) patients.

Comparison of the pre and postoperative ophthalmological outcomes is described on table 2. The mean preoperative intraocular pressure was 19.0 mmHg, which decreased to 16.3 mmHg postoperatively, a reduction of

2.7 mmHg (p < 0.001). The mean preoperative proptosis was 25.7 mm, increasing to 21.6 mm postoperatively, a reduction of 4.1 mm (p < 0.001). In addition, the mean preoperative visual acuity of 5/10 increased to 7/10 postoperatively, an improvement of 2/10 (p < 0.001).

Postoperatively, 65% of the patients reported subjective vision improvement in the operated eye, and approximately 26% patients with preoperative diplopia reported resolution of this symptom. However, keratopathy persisted in three eyes (10.7%) and optic neuropathy in one eye (4%).

Surgical complications included de novo diplopia in seven (25.9%) patients and worsened or persistent diplopia in six (22.2%) patients. Figure 2 exemplifies the case of a patient in which different surgical approaches were used for the decompression of each orbit, highlighting the impact of the technique used on the incidence of postoperative diplopia.

Discussion

TO is the most common extrathyroidal manifestation of Graves’ disease, affecting approximately 25–50% of patients, and often develop independent of thyroid disorders.<sup>3</sup>

According to the EUGOGO guidelines, TO is classified based upon its severity. Mild TO has does not have a significant impact on the quality of life and can be controlled with local therapeutic measures. Moderate to severe TO is characterized by eyelid retraction ≥ 2 mm, exophthalmos ≥ 3 mm, and transient or permanent diplopia, and requires systemic treatment. Initial management involves intravenous corticosteroids to reduce orbital edema, but this approach has a high recurrence rate. In patients with recurrence or those ineligible for surgery, alternative treatments such as orbital radiotherapy or

Table 1  
Characteristics of patients undergoing transnasal endoscopic orbital decompression

Number of patients	27
Mean age (years)	54,1
Female: male (ratio)	17 : 10
Bilateral disease, patients	13
Right: left (ratio)	17 : 23

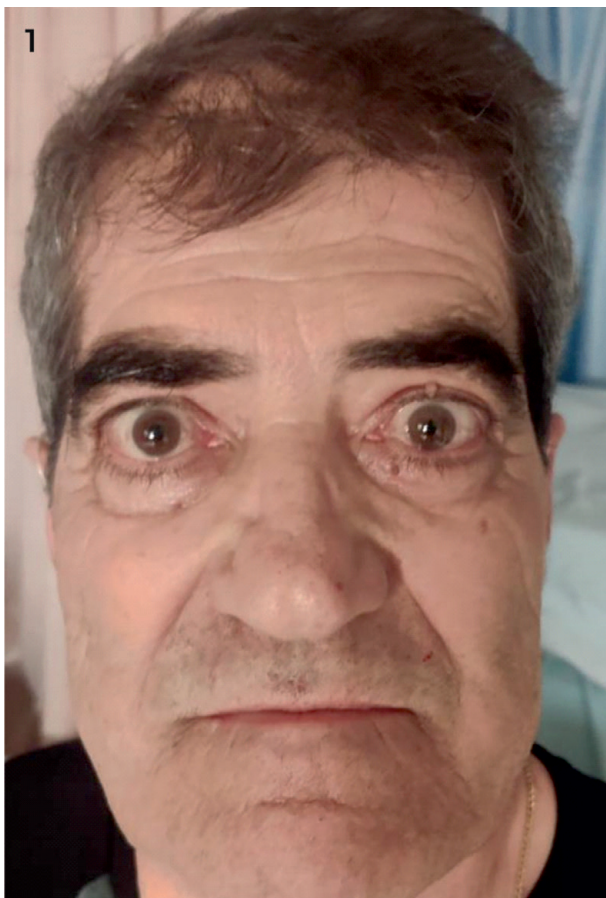Table 2  
Comparison of pre- and postoperative ophthalmological outcomes

	Preoperative	Postoperative	p-value
Intraocular pressure (mmHg), mean [range]	19,0 [11-34]	16,3 [9-22]	<0,001
Proptosis (mm), median [range]	25,73 [22-31]	21,57 [16-28]	<0,001
Visual acuity (1/10 vision), average	5/10 [11-34]	7/10 [11-34]	<0,001



**Figure 2**

Preoperative (1) and postoperative (2) photographs of a patient who underwent bilateral endoscopic orbital decompression surgery (ODS). On the left, the inferior and medial walls were decompressed preserving a modified orbital strut. On the right, the inferior and medial walls were decompressed. This case highlights the importance of techniques such as the use of an orbital strut to prevent postoperative diplopia



immunosuppression with cyclosporine or rituximab may be considered. ODS is often recommended in cases refractory to these treatments, particularly when the visual acuity is compromised by CON or keratopathy, classified as very severe TO, or when disfiguring proptosis is present.<sup>7</sup>

The transnasal endoscopic approach offers three advantages over other techniques: it provides better visualization of the medial orbital wall, particularly the orbital apex, which is often a site of substantial optic nerve damage; it enables the decompression of a second orbital wall, the floor; and it has aesthetic benefits as it prevents external scarring.<sup>8</sup> In addition, some studies have indicated that severe complications such as cerebrospinal fluid fistula or visual impairment are more

commonly associated with non-endoscopic approaches.<sup>9</sup> The most common complication following this procedure is the development of de novo diplopia, with the incidence rates ranging between 11.7–81.2%. This complication results from changed traction vectors in the extraocular muscles.<sup>10</sup> Three techniques have been described to mitigate its occurrence: the inferomedial orbital strut, which preserves a bony plate between the medial and inferior orbital walls; orbital sling, which preserves a horizontal segment of the periorbital fascia to enable fat herniation while preventing prolapse of the medial rectus muscle; and balanced decompression, which removes both the medial and lateral orbital walls to maintain the vertical vector of the orbit. The balanced decompression technique has

reportedly reduced the incidence of diplopia to 8.7–33%.<sup>11,12</sup>

In our study, seven patients (25.9%) experienced postoperative de novo diplopia, five of them subsequently undergoing strabismus correction surgery at the ophthalmology service. However, the functional outcomes of this surgery could not be objectively assessed. This study has some limitations. First, postoperative evaluations were not conducted at the same time in all patients. Additionally, since the average postoperative values were recorded after four weeks of surgery, there is insufficient information on the medium- and long-term progression of the patients. However, most postoperative changes occur within the first month after surgery.<sup>11</sup> Another limitation is the variability of the surgical technique depending on the surgeon, which may have influenced our results. In the future, the optimal surgical approach should be individualized for each patient. Cases of mild to moderate TO should be treated with more conservative methods, such as endoscopic decompression with preservation of the modified orbital strut and orbital sling, in order to minimize the incidence of postoperative diplopia.<sup>6</sup> In contrast, moderate to severe TO will likely require more aggressive decompression involving multiple orbital walls, without the use of an orbital strut or sling. Our findings indicate that transnasal ODS is safe and effective. Future studies should focus on tailoring the surgical approaches according to the disease severity, standardizing techniques, and including long-term follow-up to better characterize the patients with TO and optimize their outcomes.

### Conflict of Interests

The authors declare that they have no conflict of interest regarding this article.

### Data Confidentiality

The authors declare that they followed the protocols of their work in publishing patient data.

### Human and animal protection

The authors declare that the procedures followed are in accordance with the regulations established by the directors of the Commission for Clinical Research and Ethics and in accordance with the Declaration of Helsinki of the World Medical Association.

### Privacy policy, informed consent and Ethics committee authorization

All the processed data were based in published reports that fulfilled privacy policy and ethical considerations.

### Financial support

This work did not receive any grant contribution, funding or scholarship.

### Scientific data availability

There are no publicly available datasets related to this work.

### References

1. Tsetsos N, Daskalakis D, Tzakri D, Blioskas S, Goudakos J, Markou K. Endoscopic transnasal orbital decompression for Graves. *Rhinology*. 2020 Feb 1;58(1):2-9. doi: 10.4193/Rhin19.282.
2. Rizk SS, Papageorge A, Liberatore LA, Sacks EH. Bilateral simultaneous orbital decompression for Graves' orbitopathy with a combined endoscopic and Caldwell-Luc approach. *Otolaryngol Head Neck Surg*. 2000 Feb;122(2):216-21. doi: 10.1016/S0194-5998(00)70242-7.
3. Poślednik KB, Czerwaty K, Ludwig N, Molińska-Glura M, Jabłońska-Pawlak A, Miśkiewicz P. et al. Treatment results of endoscopic transnasal orbital decompression for Graves' orbitopathy - a single-center retrospective analysis in 28 orbits of 16 patients. *J Pers Med*. 2022 Oct 14;12(10):1714. doi: 10.3390/jpm12101714.
4. Mourits MP, Bijl H, Altea MA, Baldeschi L, Boboridis K, Currò N, et al. Outcome of orbital decompression for disfiguring proptosis in patients with Graves' orbitopathy using various surgical procedures. *Br J Ophthalmol*. 2009 Nov;93(11):1518-23. doi: 10.1136/bjo.2008.149302.
5. Eckstein A, Schittkowski M, Esser J. Surgical treatment of Graves' ophthalmopathy. *Best Pract Res Clin Endocrinol Metab*. 2012 Jun;26(3):339-58. doi: 10.1016/j.beem.2011.11.002.
6. Gioacchini FM, Kaleci S, Cassandro E, Scarpa A, Tulli M, Cassandro C. et al. Orbital wall decompression in the management of Graves' orbitopathy: a systematic review with meta-analysis. *Eur Arch Otorhinolaryngol*. 2021 Nov;278(11):4135-4145. doi: 10.1007/s00405-021-06698-5.
7. Bartalena L, Kahaly GJ, Baldeschi L, Dayan CM, Eckstein A, Marcocci C. et al. The 2021 European Group on Graves' orbitopathy (EUGOGO) clinical practice guidelines for the medical management of Graves' orbitopathy. *Eur J Endocrinol*. 2021 Aug 27;185(4):G43-G67. doi: 10.1530/EJE-21-0479.

8. Oliveira Matos T, Ribeiro H, Filipe J, Subtil J, Borges Dinis P. Simultânea descompressão da órbita e do nervo óptico na orbitopatia tiroideia. *Port J ORL* 2008 Set; 46(3):193-8. Disponível em: <https://journalsporl.com/index.php/sporl/article/view/2394/399>
9. Sellari-Franceschini S, Dallan I, Bajraktari A, Fiacchini G, Nardi M, Rocchi R. et al. Complicanze chirurgiche in pazienti sottoposti a decompressione orbitaria per oftalmopatia di Graves. *Acta Otorhinolaryngol Ital*. 2016 Aug;36(4):265-274. doi: 10.14639/0392-100X-1082.
10. Tu Y, Xu M, Kim AD, Wang MTM, Pan Z, Wu W. Modified endoscopic transnasal orbital apex decompression in dysthyroid optic neuropathy. *Eye Vis (Lond)*. 2021 Apr 28;8(1):19. doi: 10.1186/s40662-021-00238-2.
11. Woods RSR, Pilson Q, Kharytaniuk N, Cassidy L, Khan R, Timon CVI. Outcomes of endoscopic orbital decompression for graves' ophthalmopathy. *Ir J Med Sci*. 2020 Feb;189(1):177-183. doi: 10.1007/s11845-019-02043-2.
12. Massey CJ, Hink E, Kingdom TT. Endoscopic orbital decompression for thyroid eye disease. *Curr Otorhinolaryngol Rep*. 2019; 7: 147–52. doi:10.1007/s40136-019-00233-1
13. Yao WC, Sedaghat AR, Yadav P, Fay A, Metson R. Orbital decompression in the endoscopic age: the modified inferomedial orbital strut. *Otolaryngol Head Neck Surg*. 2016 May;154(5):963-9. doi: 10.1177/0194599816630722.